

Endomyocardial Biopsy in Myocarditis

Joseph G. Murphy, M.D., and Robert P. Frantz, M.D.

WHAT IS THE PROBLEM WITH CURRENT DIAGNOSTIC
TECHNIQUES FOR MYOCARDITIS?

ENDOMYOCARDIAL BIOPSY—THE TARNISHED STANDARD

Giant Cell Myocarditis

Human Immunodeficiency Virus-induced Myocarditis

Hemochromatosis

Amyloidosis

Cardiac Allograft Rejection

HISTORY OF ENDOMYOCARDIAL BIOPSY

TECHNIQUE

Right Internal Jugular Vein Approach

Femoral Vein Approach

ENDOMYOCARDIAL BIOPSY SPECIMEN PROCESSING

THE DALLAS CRITERIA FOR THE HISTOLOGIC DIAGNOSIS
OF MYOCARDITIS

COMPLICATIONS OF ENDOMYOCARDIAL BIOPSY

Cardiac Perforation

Thromboembolism

ENDOMYOCARDIAL BIOPSY IN CHILDREN

MAKING DECISIONS ABOUT ENDOMYOCARDIAL BIOPSY
IN MYOCARDITIS

CONCLUSION

The accurate diagnosis of myocarditis rests on the finding of active inflammation involving cardiac myocytes and is made either at autopsy or ante mortem by endomyocardial biopsy findings.

WHAT IS THE PROBLEM WITH CURRENT DIAGNOSTIC TECHNIQUES FOR MYOCARDITIS?

Myocarditis is defined as an inflammatory condition of the heart muscle and is caused by multiple organisms and conditions. The diagnosis of myocarditis remains a challenge, with conflicting views among clinicians and investigators as to whether clinical or histologic diagnostic criteria should predominate.¹⁻⁴ When the clinical suspicion of myocarditis (sudden onset of heart failure or ventricular arrhythmias in association with or soon after a febrile illness) accords with the histologic diagnosis, there is little diagnostic problem. However, when the clinical presentation of myocarditis is not associated with biopsy evidence of myocyte damage and T-lymphocyte infiltration, this is a dilemma.

In the Myocarditis Treatment Trial,⁵ most patients with clinically suspected myocarditis did not have biopsy evidence of myocarditis. In this trial, all patients underwent biopsy who had suspected myocarditis based on the new onset of unexplained heart failure during the 2 years preceding enrollment. The endomyocardial biopsy samples were reviewed according to the Dallas criteria by a panel of 7 pathologists and a consensus diagnosis was reached. The pathologists found histopathologic evidence of myocarditis on endomyocardial biopsy in just 214 of 2,233 patients (less than 10%). Other smaller series also reported a poor concordance between the clinical and histologic diagnoses of myocarditis, “possibly because the clinical diagnosis is wrong or the histologic criteria used by pathologists are inappropriate.”⁶

The ongoing European Study of Epidemiology and Treatment of Cardiac Inflammatory Diseases (ESETCID) has expanded the light microscopic Dallas criteria for myocarditis by including immunohistochemical variables of myocardial inflammation.⁷ Endomyocardial biopsy specimens are screened not only for infiltrating cells but also for the presence of persisting viral genome (enterovirus, cytomegalovirus, and adenovirus). This method shows inflammatory processes in the heart in 17.2% of the 3,055 patients screened. Only 182 of these patients showed a reduced ejection fraction below 45%, fulfilling the entrance criteria for the ESETCID trial. These data indicate that, in symptomatic patients, myocarditis should always be considered and relatively well-preserved left ventricular function does not exclude the diagnosis. In the ESETCID trial, viral genome was detected in 11.8% of patients (enterovirus 2.2%, cytomegalovirus 5.4%, adenovirus 4.2%).

ENDOMYOCARDIAL BIOPSY—THE TARNISHED STANDARD

Notwithstanding the above limitation, percutaneous endomyocardial biopsy remains the tarnished standard for the *in vivo* diagnosis of myocarditis.⁸ In addition to light microscopy of endomyocardial biopsy samples, the diagnosis of specific viral myocarditis conditions has improved with the advent of immunohistochemistry and the molecular biology techniques of polymerase chain reaction, *in situ* hybridization, and Southern blot.^{9,10} In addition, endomyocardial biopsy may be particularly valuable to exclude other noninflammatory causes of ventricular dysfunction such as amyloid heart disease and hemochromatosis (Fig. 15-1).¹¹⁻¹⁵ Patients who should be considered for endomyocardial biopsy include those with unexplained dilated cardiomyopathy, restrictive cardiomyopathy, and unexplained ventricular arrhythmias.¹⁶⁻¹⁸ Conditions that may be diagnosed by endomyocardial biopsy are listed in Tables 15-1 and 15-2. The decision to perform an endomyocardial biopsy depends on the perceived probability that a biopsy could lead to a diagnosis that otherwise would not be made, and that this in turn will result in a treatment different from that recommended in the absence of biopsy results (Table 15-3). Brief descriptions of some scenarios in which endomyocardial biopsy may have major implications for management are outlined below.

GIANT CELL MYOCARDITIS

Endomyocardial biopsy is the only method permitting definitive antemortem diagnosis of giant cell myocarditis. Although this disorder is rare, prompt identification of such patients is critical. Mortality rates are high, usually owing to ventricular arrhythmia or progressive heart failure, and prompt referral to a transplant center is essential. Anecdotal reports suggest that such patients may respond to aggressive immunosuppression; randomized trials are under way and should be considered for these patients. Clues to the possibility of giant cell myocarditis include the presence of complex ventricular arrhythmias that may be associated with abrupt onset of cardiac failure. Because giant cell myocarditis may recur in the transplanted heart, vigilance is required even after transplantation.

HUMAN IMMUNODEFICIENCY VIRUS-INDUCED MYOCARDITIS

Human immunodeficiency virus (HIV) infection is a well-recognized cause of myocarditis, but the exact pathogenesis of the heart muscle disease in the acquired immunodeficiency syndrome is unclear. Possible causes of heart muscle damage include “a direct action of HIV on the myocardial tissue or to an autoimmune process induced by HIV, possibly in association with other cardiotropic viruses.”¹⁹

Barbaro et al.¹⁹ performed a prospective, long-term clinical and echocardiographic follow-up study of 952 asymptomatic HIV-positive patients to assess the incidence of dilated cardiomyopathy. All patients with an echocardiographic diagnosis of dilated cardio-

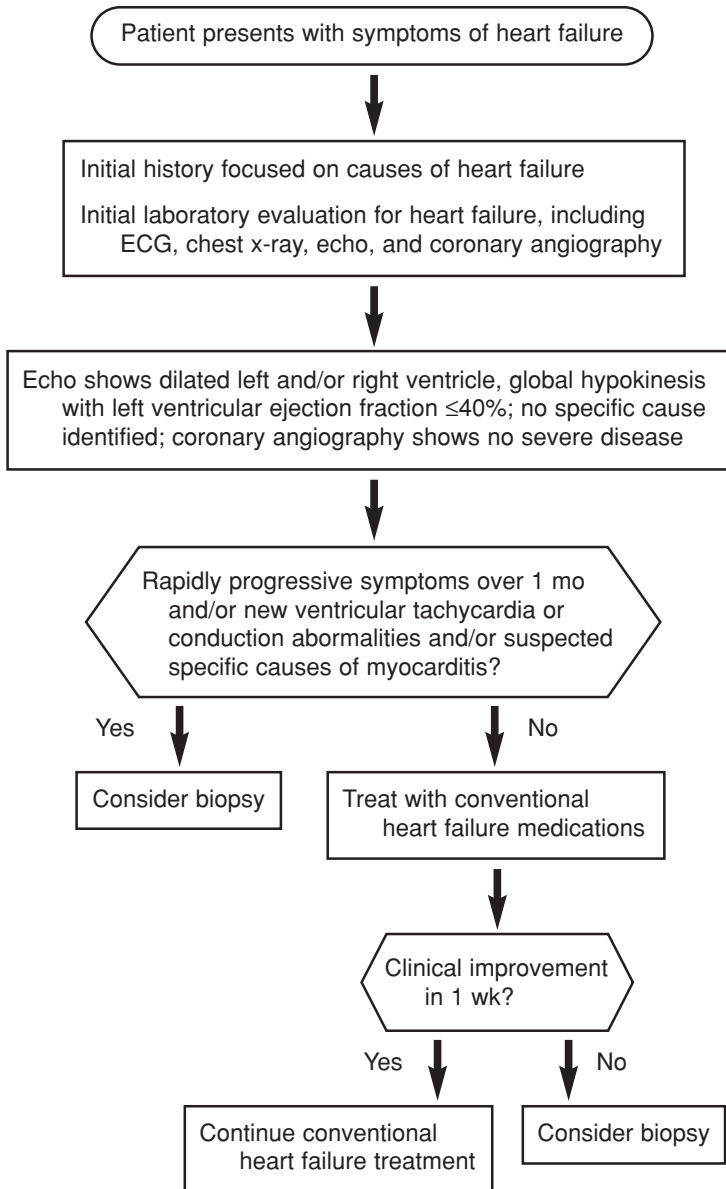


Fig. 15-1. Flow diagram for the work-up of patients with dilated cardiomyopathy. The timing of endomyocardial biopsy in patients who fail to improve on medical therapy is controversial. If the patient's left ventricular function and symptoms are stable after 1 week of treatment, additional time before endomyocardial biopsy could be considered, if appropriate in the treating physician's clinical judgment, to allow for delayed recovery to occur. *ECG*, electrocardiography; *echo*, echocardiography. (From Wu LA, Lapeyre AC III, Cooper LT. Current role of endomyocardial biopsy in the management of dilated cardiomyopathy and myocarditis. *Mayo Clin Proc* 2001;76:1030-1038. By permission of Mayo Foundation for Medical Education and Research.)

Table 15-1
Conditions That Can Be Diagnosed by Endomyocardial Biopsy

Arrhythmogenic right ventricular dysplasia
Amyloidosis
Sarcoidosis
Hemochromatosis
Myocarditis (eg, eosinophilic myocarditis, giant cell myocarditis)
Anthracycline cardiomyopathy
Storage diseases such as mucopolysaccharidoses
Carcinoid heart disease
Primary and metastatic neoplasms (eg, rhabdomyosarcoma, lymphoma)
Radiation-induced cardiac fibrosis
Cardiac allograft rejection

Table 15-2
Common Clinicopathologic Diagnoses in 1,230 Patients
With Initially Unexplained Cardiomyopathy

Diagnosis	Patients, no. (%)
Idiopathic dilated cardiomyopathy	616 (50)
Myocarditis	111 (9)
Ischemic cardiomyopathy	91 (7)
Infiltrative disease	59 (5)
Peripartum cardiomyopathy	51 (4)
Hypertension	49 (4)
Human immunodeficiency virus infection	45 (4)
Connective tissue disease	39 (3)
Substance abuse	37 (3)
Doxorubicin related	15 (1)
Other causes	111 (10)

From Wu LA, Lapeyre AC III, Cooper LT. Current role of endomyocardial biopsy in the management of dilated cardiomyopathy and myocarditis. *Mayo Clin Proc* 2001;76:1030-1038. By permission of Mayo Foundation for Medical Education and Research.

myopathy underwent endomyocardial biopsy for histologic, immunohistologic, and virologic assessment. The mean follow-up period was 60 months, and an echocardiographic diagnosis of dilated cardiomyopathy was made in 76 patients (8%), yielding a mean annual incidence rate of 15.9 cases per 1,000 patients. The incidence of dilated cardiomyopathy was higher in patients with a CD4 count of less than 400 cells per μL (compared with a CD4 count of greater than or equal to 400 cells per μL) and in those who received therapy with zidovudine. A histologic diagnosis of myocarditis was made in 63 of the patients

Table 15-3
Signs and Symptoms in Patients With Congestive Heart Failure
Who Warrant an Endomyocardial Biopsy

Acute heart failure with symptoms refractory to current medical management
Rapidly decreasing left ventricular ejection fraction with no clear etiology despite conventional therapy for heart failure
Heart failure with acutely worsening rhythm disturbances, particularly ventricular tachycardia
New heart failure with conduction disturbances, particularly nodal block (not drug induced and negative Lyme serology)
Heart failure in the setting of peripheral eosinophilia, rash, and fever
Heart failure in the setting of clinical history and/or features of secondary causes where endomyocardial biopsy may change or modify therapy:
Collagen vascular diseases (systemic lupus erythematosus, scleroderma, Marfan syndrome, polyarteritis nodosum, dermatomyositis/polymyositis)
Infiltrative and storage diseases (amyloid, sarcoid, hemochromatosis)
Giant cell myocarditis
Neoplasms

From Wu LA, Lapeyre AC III, Cooper LT. Current role of endomyocardial biopsy in the management of dilated cardiomyopathy and myocarditis. *Mayo Clin Proc* 2001;76:1030-1038. By permission of Mayo Foundation for Medical Education and Research.

(83%) with dilated cardiomyopathy. Inflammatory infiltrates were composed predominantly of CD3 and CD8 lymphocytes, with staining for major histocompatibility complex class I antigens in 71% of the patients. In the myocytes of 58 patients, HIV nucleic acid sequences were detected by in situ hybridization, and active myocarditis was documented in 36 of the 58. Among these 36 patients, 6 were also infected with coxsackievirus group B (17%), 2 with cytomegalovirus (6%), and 1 with Epstein-Barr virus (3%). Thus, myocarditis was a common finding in HIV patients with echocardiographic evidence of left ventricular dysfunction.

HEMOCHROMATOSIS

Hemochromatosis is an inherited disorder of iron metabolism. Typical manifestations include diabetes, abnormal liver function, skin pigment changes, and dilated cardiomyopathy. Serum iron studies show marked increases of iron values. An endomyocardial biopsy shows deposits of iron in the myocardium and allows the diagnosis of hemochromatosis to be made. This has significant implications for treatment and for screening of family members.

AMYLOIDOSIS

Amyloidosis is a devastating disease that results from deposits of proteinaceous material in various organs, including the heart. The precise nature of the material depends on the type

of amyloidosis (primary systemic, familial, or senile). Cardiac manifestations include exertional dyspnea, chest pain, atrial arrhythmias, conduction block, and congestive heart failure. Early in the course of cardiac involvement, left ventricular systolic function is relatively well preserved, whereas diastolic function is often abnormal, with a restrictive filling pattern. Increased wall thickness associated with low QRS voltage on the surface electrocardiogram must arouse suspicion regarding possible amyloidosis. Serum and urine immunoelectrophoresis should be performed, looking for a monoclonal gammopathy. However, this will be absent in familial and senile types of amyloidosis. Multiple possible biopsy sources such as fat aspirate or rectal biopsy may be considered, but if less invasive sites are not diagnostic, endomyocardial biopsy has a high sensitivity. Notification of the pathologist regarding the suspected diagnosis is important to be certain proper stains are performed. Patients with familial amyloidosis can be treated effectively with liver transplantation because the liver is the source of abnormal protein production. Combined heart-liver transplantation is often necessary, because cardiac involvement may be advanced at diagnosis. Selected patients with primary systemic amyloidosis may benefit from heart transplantation followed by stem cell (marrow) transplantation.

CARDIAC ALLOGRAFT REJECTION

Surveillance endomyocardial biopsies are essential in the management of cardiac transplant recipients. Such biopsies frequently allow the diagnosis and treatment of rejection before onset of symptoms, guide immunosuppressive strategies, and detect other conditions such as cytomegalovirus or toxoplasmosis infection. Accepted nomenclature for grading of cardiac allograft rejection is provided in Table 15-4.

HISTORY OF ENDOMYOCARDIAL BIOPSY

Cardiac biopsy was performed initially by means of thoracotomy beginning in the 1950s. A major advance was the development of the first percutaneous transvenous biopsy catheter. The original device consisted of 2 sharpened cups on a catheter shaft that closed when a control wire was pulled proximally. The disadvantages of this device were its size, which necessitated a surgical cutdown for venous entry, and its relative inflexibility, which made intracardiac manipulation difficult. The Stanford (Caves-Schultz) biopptome is a modification of the original design by Konno and is widely used for endomyocardial biopsy. This biopptome is relatively flexible and has a stainless steel shaft. The cutting jaws are activated by a control wire, but only 1 jaw moves while the other is fixed in position. The Stanford biopptome is designed for use via the right internal jugular vein. The curve of the shaft should be varied by the operator between biopsies to minimize repeated biopsies of the

Table 15-4
Endomyocardial Biopsy Rejection Grading

Grade	
0	No rejection
1	A = Focal (perivascular or interstitial infiltrate without necrosis) B = Diffuse but sparse infiltrate without necrosis
2	One focus only with aggressive infiltration and/or focal myocyte damage
3	A = Multifocal aggressive infiltrates and/or myocyte damage B = Diffuse inflammatory process with necrosis
4	Diffuse aggressive polymorphous ± infiltrate, ± edema, ± hemorrhage, ± vasculitis, with necrosis

same endomyocardial site. The Kawai biptome is a flexible biptome with a dial on the operator handle that controls tip movement.

An alternative strategy is to use a long sheath-guiding catheter inserted via the femoral vein in conjunction with an unguided cardiac biptome. This strategy is used with the King biptome and the long Stanford biptome.

TECHNIQUE

Endomyocardial biopsies are performed most frequently via the right internal jugular or femoral vein. Biopsies usually are performed with local anesthesia, accompanied by conscious sedation if required. Children may require general anesthesia. Fluoroscopic guidance is used in the cardiac catheterization laboratory, but some operators prefer echocardiographic guidance, either alone or combined with fluoroscopy.

RIGHT INTERNAL JUGULAR VEIN APPROACH

The patient should be supine with the neck extended and the head turned fully to the left. Elevation of the feet on a foam wedge is useful if cardiac filling pressures are low. Careful

identification of the triangle formed by the clavicle and the medial and lateral heads of the sternocleidomastoid muscle is essential. This may be facilitated by palpating and visualizing the neck while the patient slightly lifts the head from the table, resulting in activation of the appropriate muscles.

After sterile preparation and drape of the region, needle entry should be made in the upper third of the triangle, on a trajectory toward the ipsilateral nipple. A wheal is made under the skin (with a 21-gauge needle and 2% lidocaine), with gradually deeper injection along the anticipated approach to the internal jugular vein. Intermittent aspiration before advancement of the needle avoids intravascular injection of lidocaine and confirms entry to the vein. Presence of lidocaine in the syringe may result in the blood flash appearing bright, raising the question of inadvertent carotid cannulation. This can be resolved by replacement of the syringe with an empty syringe or one containing saline.

After confirmation of jugular vein location, a small nick in the skin should be made with a scalpel. The incision can be dilated slightly with blunt scissors to facilitate subsequent passage of a sheath. An 18-gauge needle with an attached syringe containing saline is then slowly advanced along the appropriate path toward the ipsilateral nipple. Pausing and aspirating while holding slight backward traction on the syringe helps the operator confirm venous cannulation. This needle is large enough to compress the vein, particularly if there is significant scar tissue from prior cannulations. This slight back and forth traction often helps achieve successful cannulation. If the vessel is difficult to locate, it may help to return to the 21-gauge needle to reconfirm location rather than guiding the 18-gauge needle in multiple directions. Particular caution is necessary when there is the temptation to direct the needle more medially, because inadvertent carotid artery puncture may occur. If this occurs, gentle pressure should be held over the puncture to reduce the risk of hematoma formation. Rarely, carotid dissection and occlusion or stroke related to emboli from thrombus or atheroma has been reported in association with inadvertent carotid puncture.

Use of ultrasound (SiteRite) should be strongly considered if there is any difficulty in locating the vein. Ultrasound can readily confirm the location of the vein and demonstrate relative location of the internal jugular vein and carotid artery. If there is doubt about which structure represents the vein, having the patient perform a Valsalva maneuver engorges the vein and makes it more obvious. Sometimes if the vein is collapsed or scarred, use of a Pediatric Introducer Set (Cook Inc., Bloomington, IN) helps, because the 18-gauge needle may compress the vein and make cannulation difficult. The Micro-puncture set includes a 21-gauge needle, through which a 0.018-inch nitinol wire is advanced. A 4.0F catheter is placed over the wire. After removal of the inner dilator, a standard 0.038-inch J wire can then be placed, followed by a larger sheath. Fluoroscopy can confirm appropriate wire position, because occasionally the wire deflects toward the arm instead of advancing toward the right atrium. If multiple prior biopsies have been

performed, passage of dilators of gradually increasing size from 6F up to the size of the required sheath facilitates placement.

A 9F sheath is required if a standard reusable Caves-Schultz-Scholten bioptome will be used. A 7F sheath is adequate for disposable bioptomes such as the Jawz or Bipal devices.

After placement, the sheath should be aspirated and flushed with saline. With fluoroscopic guidance, the bioptome is advanced with the tip curving medially until the tricuspid valve is crossed. Localization in the right ventricle can be confirmed by the occurrence of ventricular ectopic beats. This is not trivial; if the operator is not attentive, it is possible inadvertently to direct the bioptome down the inferior vena cava and medially into the liver and to obtain samples of liver. To direct the bioptome to the apical portion of the ventricular septum may require slight back and forth movement to keep the tip free, with slight rotation to redirect the tip. If any resistance is met, the bioptome should be withdrawn slightly and redirected. The bioptome should be advanced fully across the tricuspid valve, and, using fluoroscopy to visualize the heart borders, directed to the apical portion of the ventricular septum. Rotation of the fluoroscopy unit to a left anterior oblique position can help confirm appropriate direction of the bioptome, followed by return to the anteroposterior position to establish position relative to the tricuspid apparatus. Failure to advance the bioptome sufficiently distally in the right ventricle may result in damage to the tricuspid apparatus, leading to tricuspid insufficiency. This complication is unfortunately rather common in transplant recipients who have had dozens of biopsies. It is usually well tolerated, but sometimes it results in right-sided heart failure that is difficult to manage, particularly if there is an element of pulmonary hypertension.

After gentle advancement to the apical region of the ventricular septum, the bioptome should be withdrawn slightly, the jaws opened, and the bioptome advanced gently against the septum. For patients who have not had multiple prior biopsies, gentle pressure is adequate to obtain tissue (Fig. 15-2). This is particularly important in patients with dilated cardiomyopathy, who may have a thin-walled, soft myocardium. Patients with multiple prior biopsies may require slightly more pressure because of the presence of endomyocardial scar. Four or 5 specimens are generally obtained, placed promptly in appropriate preservative, and sent for pathologic review. The pieces should be inspected before submission. If multiple prior biopsies have been performed (eg, in cardiac transplant recipients), some of the pieces may appear pearly white, indicating that mostly scar and little myocardium is present. Such pieces are not helpful for pathologic examination, and better samples should be sought.

Excess force risks perforation of the right ventricle if the bioptome is not properly directed. Sharp pleuritic chest pain is a sign of likely perforation. If this occurs, blood pressure should be observed closely, and emergent echocardiography done to seek evidence of pericardial effusion. Equipment for placement of a pericardial catheter should be available.

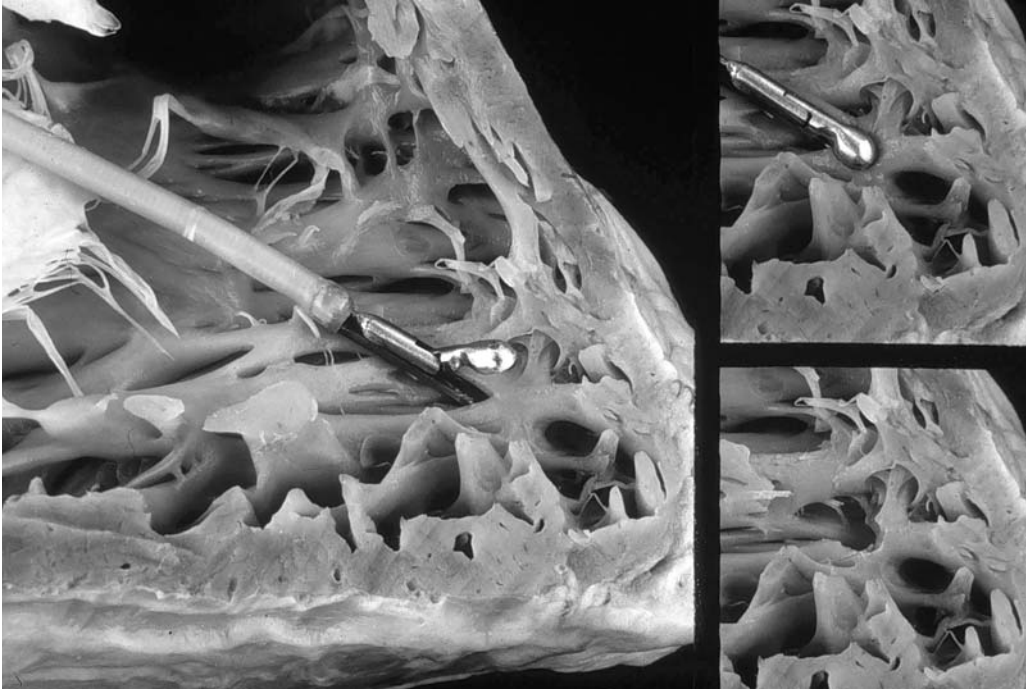


Fig. 15-2. Endomyocardial biopsy simulation in a cadaveric heart. (Courtesy of William D. Edwards, M.D.)

A hoarse voice due to injury of the recurrent laryngeal nerve has rarely been reported to occur after endomyocardial biopsy. This may be transient or occasionally may last for months.

Fistulae have been reported between the coronary artery and the right ventricle. These are visualized on surveillance coronary angiography and appear not to be associated with any clinical sequelae.

Choice of a bioptome reflects operator preference. The reusable Scholten bioptome is nicely steerable, holds its shape well, and has a blunt tip. However, it does require sterilization after each use and must be resharpened periodically. If it is used when it is dull, which may not be obvious by simple inspection, it may tear larger pieces of endocardium than desired. This is particularly true in cardiac transplant recipients who have had multiple biopsies and therefore have areas of scarring along the endocardium. Accordingly, if excess resistance is felt on efforts to withdraw the bioptome, it is best to release the jaws and reposition, rather than exerting heavier traction. The disposable bioptomes do not hold their shape as well as the Scholten bioptomes and are somewhat more awkward to position appropriately.

FEMORAL VEIN APPROACH

The femoral vein approach has some advantages and disadvantages relative to the jugular vein approach. Advantages include freedom from risks inherent in the jugular approach such as inadvertent carotid puncture. In addition, some patients prefer the femoral approach; it is less unpleasant than to have procedures through the neck. If multiple prior biopsies have been performed from the neck, scar tissue may begin to limit access and create more discomfort with sheath placement, in which case moving to the femoral approach may help. Disadvantages of the femoral approach include the need for a long sheath in which clots may develop, risk of deep venous thrombosis, and need for patients to remain supine for approximately 30 minutes after sheath removal. In addition, directing the bioptome across the tricuspid valve and to the appropriate region of the ventricle is difficult sometimes. The bioptomes used from the femoral approach may yield smaller samples than those from the neck, but usually they still provide adequate samples for accurate pathologic diagnosis.

After cannulation of the femoral vein by standard technique, a wire is advanced with fluoroscopic guidance. A 7 or 8F Mullins sheath of the type used for transeptal catheterization is advanced to the right ventricle. Sometimes putting some curvature on the end of the wire is necessary to help direct the system to the right ventricle. A Mullins sheath with a sidearm can facilitate aspiration and flushing of the sheath. Alternatively, a Mullins sheath without a sidearm and with a Tuohy-Borst hemostasis device of the type used for angioplasty can facilitate bioptome passes. The Mullins sheath should be positioned in the right ventricle pointing toward the apical portion of the ventricular septum. It may tend to sit too far down toward the inferior wall, in which case withdrawing it slightly may allow the bioptome to point more toward the septum. If there is doubt about the right ventricular location of the sheath, hooking it up to pressure helps to confirm right ventricular location.

With the Mullins tip free in the right ventricle, a long reusable Scholten bioptome or a disposable bioptome is passed to the right ventricular apical septum. Rotating the bioptome and moving it back and forth are necessary for proper positioning. Some forward pressure on the Mullins sheath and the bioptome is often necessary to seat the bioptome against the endocardium, because some of the forward pressure simply flexes the body of the bioptome. After the jaws are closed, *both* the bioptome and the Mullins sheath should be withdrawn gently until the bioptome comes free from the endocardium. Failure to hold back pressure on the Mullins sheath will pull the Mullins sheath over the bioptome and into the endocardium, risking right ventricular perforation if the bioptome does not come free easily. Once the bioptome is free, the Mullins sheath can be advanced slightly to maintain position in the right ventricle. It is important to aspirate and flush the sheath carefully after each pass of the bioptome to clear the

sheath of possible thrombus. Appropriate flushing of the sheath during exchanges minimizes the risk of entraining air. After retrieval of the specimens, the sheath should be withdrawn into the inferior vena cava and then removed in the recovery room, where local pressure ensures hemostasis.

A specially designed catheter produced by Cordis (Tampa Bay guiding catheter) sits more easily in the right ventricle than a Mullins sheath. However, the bioptomes that fit through this catheter are small, resulting in retrieval of small samples. They are often adequate for pathologic examination, and some operators prefer this system. Other disposable bioptome and sheath systems are available.

ENDOMYOCARDIAL BIOPSY SPECIMEN PROCESSING

Multiple biopsy specimens (usually 5 to 8 samples) are taken from different biopsy sites in the ventricular septum. There is a tendency for the bioptome to gravitate to the same biopsy locations because the vascular entry site is fixed by the vascular sheath and the entry into the right ventricle, by the tricuspid valve orifice. Biopsy specimens are placed in 10% formalin for light microscopy and 2.5% buffered glutaraldehyde if electron microscopy is needed. Special preparation and immediate freezing may be required for immunologic staining or molecular biologic studies of RNA or DNA.

THE DALLAS CRITERIA FOR THE HISTOLOGIC DIAGNOSIS OF MYOCARDITIS

Before the acceptance of the Dallas criteria for the histologic diagnosis of myocarditis, considerable interobserver variability existed in the interpretation of endomyocardial biopsy samples. Shanes et al.²⁰ submitted biopsy specimens from 16 patients with dilated cardiomyopathy to 7 experienced cardiac pathologists who independently reviewed the same slides and assessed each for fibrosis, hypertrophy, nuclear changes on a 0 to 3 scale, and mean lymphocyte count per high-power field. The prevalence of all observed variables varied widely; significant fibrosis ranged from 25% to 69%, hypertrophy from 19% to 88%, nuclear changes from 31% to 94%, and abnormal lymphocyte count from 0% to 38%. One or more pathologists diagnosed definite or possible myocarditis in 11 of the 16 patients. Of these 11 patients, 3 pathologists agreed about 3 and 2 pathologists agreed about 5. Myocarditis was diagnosed by 1 pathologist in 3 cases. The conclusion of this study was that quantitative and standardized methods are needed to increase diagnostic consistency in the histologic diagnosis of myocarditis.

COMPLICATIONS OF ENDOMYOCARDIAL BIOPSY

Endomyocardial biopsy is associated with an overall complication rate of 1% to 2% in most large series. However, these series include a high proportion of post cardiac transplant patients undergoing routine rejection surveillance, who may have a lower risk of complication than myocarditis patients. Myocarditis patients undergoing biopsy frequently have poor ventricular function and heart failure and are prone to ventricular arrhythmias. It is important to biopsy the interventricular septum and not the right ventricular apex, which may be only a few millimeters thick in some patients. Accurate anatomic localization of the biopsy site in the interventricular septum may be aided by biplane cardiac fluoroscopy or echocardiography.²¹

CARDIAC PERFORATION

The most important specific complication of endomyocardial biopsy is cardiac perforation, which can lead rapidly to cardiac tamponade and cardiac arrest. Cardiac perforation occurs in about 0.3% of patients. Patients with prior cardiac surgical procedures or post transplantation are relatively protected from cardiac perforation and tamponade by an adherent pericardium overlying the right ventricle.²²⁻²⁴ Death due to endomyocardial biopsy occurs in approximately 1 of 1,000 procedures.

Cardiac perforation usually is heralded by the development of pleuritic chest pain. The presence of blood in the pericardial space frequently elicits a vasovagal-type reflex with bradycardia and hypotension. The biopsy specimen may be white and glistening, suggesting the presence of pericardium, and may float in formalin fixative owing to the presence of epicardial fat. Note that in patients who have had many previous myocardial biopsies such as cardiac transplant recipients, biopsy of a previous endomyocardial scar site may yield fibrotic-looking material that may simulate pericardium.

If myocardial perforation is suspected, systemic arterial pressure and right atrial pressure should be monitored for evidence of tamponade and an emergency echocardiogram should be performed. Fluoroscopy may show obliteration of the normal right-sided cardiac motion in tamponade, but findings on Doppler echocardiography are more specific and occur earlier in incipient tamponade. Emergency, percutaneous, echo-guided pericardial catheter drainage should be performed if evidence of incipient tamponade is present. Most perforations induced by endomyocardial biopsy are self-sealing and rarely require surgical exploration. The exceptions are in patients with severe pulmonary hypertension and coagulopathies, including patients receiving anticoagulant therapy. It is our practice to decline biopsy in patients with an international normalized ratio greater than 1.5 and in patients who have received heparin recently. Atropine, intravenous fluids, and inotropic agents are helpful temporizing measures before pericardiocentesis in patients with cardiac perforation.

THROMBOEMBOLISM

The risk of thromboembolism from either tissue or thrombus from the biopsy site is higher in left ventricular biopsy. Right-sided thromboembolism can be due to thrombus from the venous access sheath or air aspiration as a result of low central venous pressure, especially with the internal jugular approach.

In general, myocarditis that is not patchy will be diagnosed if 4 to 5 right ventricular biopsy samples are obtained. The possibility of some small added diagnostic yield by taking biopsy samples of the left ventricle in addition to the right is outweighed by the small attendant risk of systemic embolism. Transient nonsustained ventricular arrhythmias are common at the time of ventricular biopsy and indeed tend to confirm the ventricular location of the biopome. Conduction disturbances may occur from mechanical trauma to the conduction system and are usually transient. Injury to the tricuspid valve may occur as a result of injury to the chordae tendineae.²⁵ Complications associated with internal jugular sheath placement include vasovagal reactions, pneumothorax, inadvertent carotid artery puncture, and hematoma formation.²²

ENDOMYOCARDIAL BIOPSY IN CHILDREN

Pophal et al.²⁶ reviewed their experience with endomyocardial biopsy in children. This was a retrospective review of the morbidity and mortality of 1,000 consecutive endomyocardial biopsy procedures in 194 children (right ventricle 986, left ventricle 14) performed from July 1987 through March 1996. Indications for endomyocardial biopsy included heart transplant rejection surveillance (846) and evaluation of cardiomyopathy or arrhythmia for possible myocarditis (154). Thirty-seven procedures (4%) were performed on patients receiving intravenous inotropic support. There was 1 biopsy-related death, due to cardiac perforation, in a 2-week-old infant with dilated cardiomyopathy. There were 9 perforations of the right ventricle: 8 in patients with dilated cardiomyopathy and 1 in a transplant recipient. The transplant patient did not require immediate intervention; 2 patients required pericardiocentesis alone, and 6 underwent pericardiocentesis and surgical intervention. All 9 perforations were from the femoral venous approach ($P < 0.01$). Multivariate analysis demonstrated that the greatest risk of perforation occurred in children being evaluated for possible myocarditis ($P = 0.01$) and in those requiring positive inotropic support ($P < 0.01$). Other complications included arrhythmia ($n = 5$) and single cases of coronary-cardiac fistula, flail tricuspid leaflet, pneumothorax, hemothorax, endocardial stripping, and seizure. The authors concluded that the risk of endomyocardial biopsy is highest in sick children with suspected myocarditis receiving intravenous inotropic support. However, endomyocardial biopsy can be performed safely with low morbidity in pediatric heart transplant recipients.²⁷

MAKING DECISIONS ABOUT ENDOMYOCARDIAL BIOPSY IN MYOCARDITIS

Most patients with dilated cardiomyopathy who have endomyocardial biopsy do not have any change in their clinical therapy as a result of the biopsy. About 80% to 90% of patients who have endomyocardial biopsy either because of new-onset heart failure or because of clinically suspected myocarditis have the nonspecific histologic finding of myocyte hypertrophy and fibrosis. About 10% to 20% of endomyocardial biopsies give definitive information for a specific diagnosis such as myocarditis, amyloidosis, sarcoidosis, or hemochromatosis. In less than half of the patients in whom a specific diagnosis is made, there is a change in clinical treatment based solely on the endomyocardial biopsy result.

The decision to proceed with an endomyocardial biopsy in a patient with suspected myocarditis should balance the expected gain from an accurate diagnosis with its attendant therapeutic implications against the small risk of a major procedural complication. Most patients with clinically suspected myocarditis do not have biopsy-proven myocarditis, and thus immunosuppressive therapy based solely on a clinical diagnosis of myocarditis is unwise. The Clinical Trial of Immunosuppressive Therapy for Myocarditis did not show a beneficial effect of immunosuppressive therapy (prednisone with either cyclosporine or azathioprine) on left ventricular function at 28 weeks in patients with biopsy-proven active myocarditis. The conclusion of this study does not apply to patients with other forms of histologically proven myocarditis that were not studied, including giant cell myocarditis, peripartum myocarditis, hypersensitivity myocarditis, and cardiac sarcoidosis.

ESETCID addresses some of the problems encountered in the Clinical Trial of Immunosuppressive Therapy for Myocarditis by distinguishing between different forms of myocarditis. Patients with cytomegalovirus-induced myocarditis will be treated by hyperimmunoglobulin or placebo. Patients with enterovirus-positive myocarditis will receive interferon- α or placebo. Patients with virus-negative myocarditis, which is considered autoimmune, will be treated with immunosuppression or placebo. The primary end point of this study will be an improvement in ejection fraction of more than 5%.

Hrobon et al.²⁸ used decision analysis to determine the efficacy (5-year risk reduction in mortality or transplantation) that a treatment for myocarditis would require to favor a biopsy-guided approach over conventional therapy. The prevalence of myocarditis among patients with dilated cardiomyopathy was estimated from the published literature (including or excluding borderline myocarditis) as 16% and 11%, respectively; sensitivity of endomyocardial biopsy diagnosis of myocarditis, 63% and 50%, respectively; probability of 5-year transplantation-free survival, 55%; specificity of endomyocardial biopsy diagnosis, 95.4%; mortality rate of endomyocardial biopsy, 0.4%; side effects resulting in withdrawal of immunosuppressive treatment, 4%; and 6-month mortality rate for immunosuppressive treatment, 0.1%.

The authors concluded that a therapy that decreased the rate of death or transplantation by 12.7% and 7.1% for patients, excluding or including borderline myocarditis, respectively, favored endomyocardial biopsy. Sensitivity analysis indicated that therapeutic efficacy was influenced by myocarditis prevalence and biopsy-related death but not by accuracy of biopsy or probability of immunosuppressive therapy side effects. Randomized trials powered to detect 7% and 25% reductions in death and transplantation would require 5,790 and 380 end points, respectively. Decreasing the rate of death or transplantation by 7.1% offsets therapy side effects, endomyocardial biopsy-related death, and inaccuracies in histologic diagnosis. Variables in this decision analysis that significantly affected outcome included the prevalence of myocarditis and the sensitivity of the diagnostic techniques.

The initial therapy for patients with suspected myocarditis is hospital admission for bed rest and electrocardiogram monitoring and vasodilators to decrease vascular resistance and lower left ventricular filling pressures. Patients with acute fulminant myocarditis and hemodynamic deterioration may benefit from short-term circulatory support with left ventricular-assist devices. The rationale for this approach is that short-term left ventricular support reduces wall stress and allows time for improvement in myocyte function.

Immunosuppressive therapy is not recommended in patients with acute infectious or postinfectious myocarditis, but a small subset of patients with noninfectious myocarditis due to giant cell myocarditis, scleroderma, lupus erythematosus, polymyositis, or sarcoidosis may benefit from immunosuppressive therapy.

A beneficial treatment of inflammatory heart disease is still difficult and not yet validated by a study with patient numbers sufficient to allow statistical analysis. The ESETCID addresses problems of etiology, pathogenesis, and specific treatment of myocarditis. It is the first multicenter, double-blind placebo-controlled randomized study, apart from the Myocarditis Treatment Trial, to distinguish between different forms of myocarditis. In the ESETCID, patients with acute or chronic myocarditis are treated specifically according to the etiology of the disease. This trial may yield a better understanding of the course of myocarditis, leading to more specific treatment, which may in turn decrease the number of patients with post-myocardial infarction heart muscle disease who require heart transplantation as a final therapeutic remedy.

CONCLUSION

Endomyocardial biopsy remains the tarnished standard for the diagnosis of myocarditis and should be considered in all patients with unexplained new-onset heart failure, particularly if complicated by ventricular tachycardia or high-grade heart block. The expectation of both clinician and patient should be that a specific diagnosis will be made in a minority of

cases and that even smaller number of patients will have a change in clinical treatment. However, in this subset of patients endomyocardial biopsy may initiate lifesaving treatment.

REFERENCES

1. Fowles RE, Mason JW. Role of cardiac biopsy in the diagnosis and management of cardiac disease. *Prog Cardiovasc Dis* 1984;27:153-172.
2. Parrillo JE, Aretz HT, Palacios I, Fallon JT, Block PC. The results of transvenous endomyocardial biopsy can frequently be used to diagnose myocardial diseases in patients with idiopathic heart failure. Endomyocardial biopsies in 100 consecutive patients revealed a substantial incidence of myocarditis. *Circulation* 1984;69:93-101.
3. Davies MJ, Ward DE. How can myocarditis be diagnosed and should it be treated? *Br Heart J* 1992;68:346-347.
4. Caves PK, Stinson EB, Billingham M, Shumway NE. Percutaneous transvenous endomyocardial biopsy in human heart recipients. Experience with a new technique. *Ann Thorac Surg* 1973;16:325-336.
5. Mason JW, O'Connell JB, Herskowitz A, Rose NR, McManus BM, Billingham ME, Moon TE. A clinical trial of immunosuppressive therapy for myocarditis. The Myocarditis Treatment Trial Investigators. *N Engl J Med* 1995;333:269-275.
6. McKenna WJ, Davies MJ. Immunosuppression for myocarditis. *N Engl J Med* 1995;333:312-313.
7. Hufnagel G, Pankuweit S, Richter A, Schonian U, Maisch B. The European Study of Epidemiology and Treatment of Cardiac Inflammatory Diseases (ESETCID). First epidemiological results. *Herz* 2000;25:279-285.
8. Aretz HT, Billingham ME, Edwards WD, Factor SM, Fallon JT, Fenoglio JJ Jr, Olsen EG, Schoen FJ. Myocarditis. A histopathologic definition and classification. *Am J Cardiovasc Pathol* 1987;1:3-14.
9. Davydova J, Pankuweit S, Crombach M, Eckhardt H, Strache D, Faulhammer P, Maisch B. Detection of viral and bacterial protein in endomyocardial biopsies of patients with inflammatory heart muscle disease? *Herz* 2000;25:233-239.
10. Pankuweit S, Portig I, Eckhardt H, Crombach M, Hufnagel G, Maisch B. Prevalence of viral genome in endomyocardial biopsies from patients with inflammatory heart muscle disease. *Herz* 2000;25:221-226.
11. Sugrue DD, Holmes DR Jr, Gersh BJ, Edwards WD, McLaran CJ, Wood DL, Osborn MJ, Hammill SC. Cardiac histologic findings in patients with life-threatening ventricular arrhythmias of unknown origin. *J Am Coll Cardiol* 1984;4:952-957.
12. Billingham ME, Cary NR, Hammond ME, Kemnitz J, Marboe C, McCallister HA, Snovar DC, Winters GL, Zerbe A. A working formulation for the standardization of nomenclature in the diagnosis of heart and lung rejection: Heart Rejection Study Group. The International Society for Heart Transplantation. *J Heart Transplant* 1990;9:587-593.
13. Feldman AM, McNamara D. Myocarditis. *N Engl J Med* 2000;343:1388-1398.
14. Fenoglio JJ Jr, Ursell PC, Kellogg CF, Drusin RE, Weiss MB. Diagnosis and classification of myocarditis by endomyocardial biopsy. *N Engl J Med* 1983;308:12-18.
15. Lie JT. Myocarditis and endomyocardial biopsy in unexplained heart failure: a diagnosis in search of a disease. *Ann Intern Med* 1988;109:525-528.
16. Liangos O, Neure L, Kuhl U, Pauschinger M, Sieper J, Distler A, Schwimmbeck PL, Braun J. The possible role of myocardial biopsy in systemic sclerosis. *Rheumatology (Oxford)* 2000;39:674-679.

17. Jurkovich D, de Marchena E, Bilsker M, Fierro-Renoy C, Temple D, Garcia H. Primary cardiac lymphoma diagnosed by percutaneous intracardiac biopsy with combined fluoroscopic and transesophageal echocardiographic imaging. *Cathet Cardiovasc Interv* 2000;50:226-233.
18. Maisch B. Endomyocardial biopsy in myocarditis. [German.] *Dtsch Med Wochenschr* 2000;125 Suppl 1:S15.
19. Barbaro G, Di Lorenzo G, Grisorio B, Barbarini G. Incidence of dilated cardiomyopathy and detection of HIV in myocardial cells of HIV-positive patients. Gruppo Italiano per lo Studio Cardiologico dei Pazienti Affetti da AIDS. *N Engl J Med* 1998;339:1093-1099.
20. Shanes JG, Ghali J, Billingham ME, Ferrans VJ, Fenoglio JJ, Edwards WD, Tsai CC, Saffitz JE, Isner J, Furener S, Subramanian R. Interobserver variability in the pathologic interpretation of endomyocardial biopsy results. *Circulation* 1987;75:401-405.
21. Miller LW, Labovitz AJ, McBride LA, Pennington DG, Kanter K. Echocardiography-guided endomyocardial biopsy. A 5-year experience. *Circulation* 1988;78:III99-III102.
22. Deckers JW, Hare JM, Baughman KL. Complications of transvenous right ventricular endomyocardial biopsy in adult patients with cardiomyopathy: a seven-year survey of 546 consecutive diagnostic procedures in a tertiary referral center. *J Am Coll Cardiol* 1992;19:43-47.
23. Mason JW. Techniques for right and left ventricular endomyocardial biopsy. *Am J Cardiol* 1978;41:887-892.
24. Tsang TSM, Freeman WK, Barnes ME, Reeder GS, Packer DL, Seward JB. Rescue echocardiographically guided pericardiocentesis for cardiac perforation complicating catheter-based procedures. The Mayo Clinic experience. *J Am Coll Cardiol* 1998;32:1345-1350.
25. Braverman AC, Copley SE, Mudge GH, Lee RT. Ruptured chordae tendineae of the tricuspid valve as a complication of endomyocardial biopsy in heart transplant patients. *Am J Cardiol* 1990;66:111-113.
26. Pophal SG, Sigfusson G, Booth KL, Bacanu SA, Webber SA, Ertedgui JA, Neches WH, Park SC. Complications of endomyocardial biopsy in children. *J Am Coll Cardiol* 1999;34:2105-2110.
27. Pass RH, Trivedi KR, Hsu DT. A new technique for endomyocardial biopsy in infants and small children. *Cathet Cardiovasc Interv* 2000;50:441-444.
28. Hrobon P, Kuntz KM, Hare JM. Should endomyocardial biopsy be performed for detection of myocarditis? A decision analytic approach. *J Heart Lung Transplant* 1998;17:479-486.